

THE VALUE OF COMPUTED TOMOGRAPHY IN THE DIAGNOSIS OF PHAEOCHROMOCYUOMA

By

Mahmoud Kadry; Mahmoud Abou El Fadl and Mostafa Sombol

From Department OF Radiology Faculty OF Medicine, Al-Azhar University.

Abstract : Nine cases (4 males and 5 females) their ages ranging from 31 to 62 years with suspected phaeochromocytoma were assessed. CT proved to be the most valuable single diagnostic modality for the assessment of phaeochromocytoma whether in origin or ectopic and even as small as 0.5 cm in diameter.

قيمة الاشعة المقطعية بالكمبيوتر فى تشخيص ورم الغدة الكظرية (فيوكروموسيتوما)

د . محمود أحمد قدرى ، د . محمود أبو الفضل ود . مصطفى سنبل

أجرى هذا البحث على عدد ٩ حالات ، ٤ ذكور و ٥ اناث تتراوح اعمارهم بين ٣١ و ٦٢ سنة يشكون من اعراض ورم الغدة الكظرية (فيوكروموسيتوما) وهو ارتفاع شديد فى ضغط الدم وارتفاع فى نسبة الادرينالين والنورادرينالين فى الدم .

وقد تم الفحص لجميع المرضى بواسطة الاشعة المقطعية بالكمبيوتر وثبت انها الفحص المثالى والوحيد الذى يوضح اى ورم سواء فى مكانه الطبيعى (الغدة الكظرية) او فى غيرها كما إتضح من الفحص وجود هذا الورم فى جدار المثابة ، كما يمكن تحديد الاورام الصغيرة والتي قد تصل الى ٥ مم فى الحجم ولا يمكن رؤيتها باى وسيلة إشعاعية اخرى .

Introduction :

Phaeochromocytoma has proved to be the commonest adrenal tumour. The classical clinical presentation is attacks of paroxysmal hypertension accompanied by headach, sweating, palpitation, anxiety and tremor. The attacks may last from 15 minutes to an hour and may occur several times an week or even a day.

50% of adult cases present with sustained hypertension (Sutton, 1987). The present study was therefore undertaken to assess the usefulness, and accuracy of computed tomography in diagnosis of phaeochromocytoma.

Material and Methods :

This study was done at Hafez Sherif CT. center & Al-Hussien Hospital, Faculty of Medicine, Al-Azhar University using general electric CT scans. It was performed on 9 cases with clinical and laboratory manifestations of phaeochromocytoma. They were 4 males and 5 females, their ages ranging from 31-62 years All the cases were subjected to full clinical examination including history, general and endocrinological examination as well as laboratory, conventional plain radiography excretory urography and ultrasonography, prior to CT abdominal scanning.

Eight cases had a long history of hypertension whether sustained or recurrent ranging from 190/110 mm Hg to 260/150 mm Hg. One case was normotensive but had medullary thyroid carcinoma (Sipple syndrome).

All the examined cases had a very high level of catecholamines ranging from 340 to 750 Ug (normal 10-100Ug).

Hechnique: All the patients were given 480 to 750 ml of 1-2% solution of sodium diatrizoate (gastrografin) 30 minutes before CT scanning and another 250 ml of the same solution 5 minutes before scanning. This regimen identifies both the small bowel and duodenum and thus permits the adrenal glands to be easily differentiated from adjacent bowel.

CT scans of the adrenal gland were performed using the small or medium calibration fields with the patient supine and the CT gantry an 0° angulation. Slice thickness of 1.5 or 5 mm were used.

Contiguous non-overlapping CT scans were usually sufficient, and CT scans should encompass at least 1 cm above and below each adrenal gland. The majority of patients could be scanned satisfactorily without intravenous administration of contrast material. Occasionally in patients with a paucity of retroperitoneal fat, the CT scans may have to be repeated after intravenous administration of contrast material to distinguish the adrenal gland from adjacent vessels, the upper pole of the kidney, the liver, and/or pancreas (Pillari et al 1982).

When phaeochromocytoma was diagnosed clinically and laboratory and no masses were found at the suprarenals, the whole abdomen and pelvis were examined to detect ectopic phaeochromocytoma.

Results :

The results of the examined cases with their CT diagnosis were described in Table (1).

Seven of the nine cases of phaeochromocytoma were found in the right suprarenal gland ranging from 1,5 to 7 cm in diameter, 5 of them appeared as solid soft tissue density related to the right adrenal gland (Fig. 1 & 2).

Two of the cases appeared as relatively hypodense, well defined masses and showed patchy enhancement after contrast administration (Fig. 3 A & B).

One patient of the nine proved clinically to have bilateral phaeochromocytoma, with medullary thyroid carcinoma (Sipple syndrome) and the patient was normotensive (Fig. 4).

One case was ectopic arising in the wall of the bladder, the patient was diagnosed clinically and laboratory to have phaeochromocytoma but CT of the abdomen revealed normal suprarenal gland and the examination was continued to the pelvis and showed phaeochromocytoma in the posterior wall of the bladder (right side) (Fig. 5).

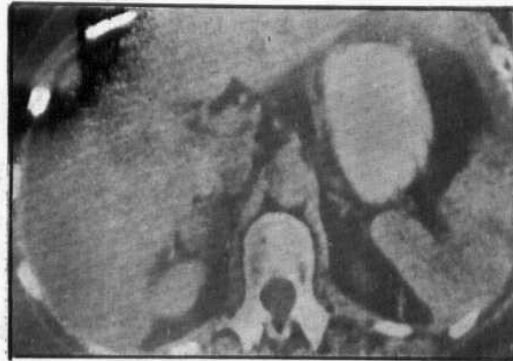


Fig. 1

Solid right suprarenal phaeochromocytoma having an attenuation value of 40 H due to a high fat content as compared with that of normal left adrenal gland, liver and kidney.

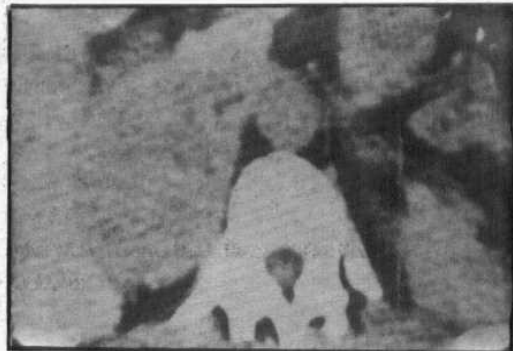


Fig. 2

Solid right suprarenal phaeochromocytoma 7 cm in diameter.

Discussion :

There are number of imaging studies that can be used in the diagnosis of phaeochromocytoma. Plain abdominal roentgenography can detect adrenal calcification and large non calcified adrenal neoplasm but has proved to be an insensitive method of demonstrating the majority of adrenal abnormalities.

TABLE 1
THE RESULTS OF INVESTIGATIONS

Case No.	Age & sex	Plain X-Ray	I.V.P	Ultrasound	CT Scanning
1	31-F	Normal	Normal	Rt-echogenic mass 3 cm	Rt-adrenal mass, solid with no enhancement.
2	48-F	Normal	Normal	Normal	Rt-adrenal mass, hypodense, with patchy enhancement.
3	42-M	Normal	A large mass displacing the right right kidney downward	Large right echogenic mass 7cm in diameter related to upper pole of the kidney	Rt-adrenal mass, solid 7 cm in diameter, with no enhancement.
4	53-M	Normal	Normal	Rt-echogenic mass, 4 cm	Rt-adrenal mass, hypodense, with patchy enhancement.
5	62-M	Normal	Normal	Normal	Rt adrenal mass, solid, 1.5 cm in diameter.
6	59-M	Normal	Normal	Lt-echogenic mass, 3 cm	Bilateral adrenal masses, 3 cm on the left and 1.8 cm on the right. the patient has medullary thyroid carcinoma.
7	37-M	Normal	Normal	Normal	Rt-adrenal mass, solid, with no enhancement.
8	46-F	Normal	Normal	Normal	Rt-adrenal mass, solid with no enhancement.
9	35-F	Normal	Normal	Normal	Ectopic in the posterior portion of right bladder wall.

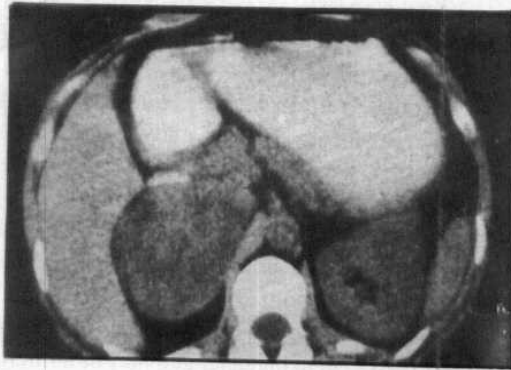


Fig. 3 (A)

Solid hypodense right suprarenal phaeochromocytoma having an attenuation value of 20 H.

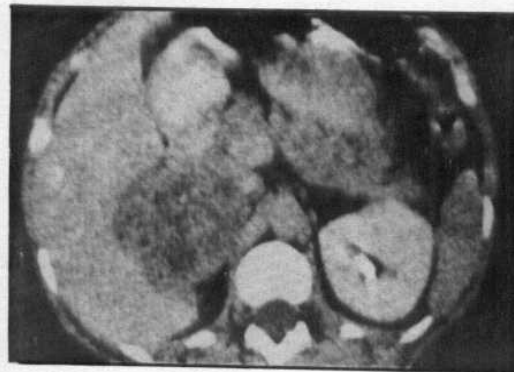


Fig. 3 (B)

After contrast injection showing patchy enhancement.

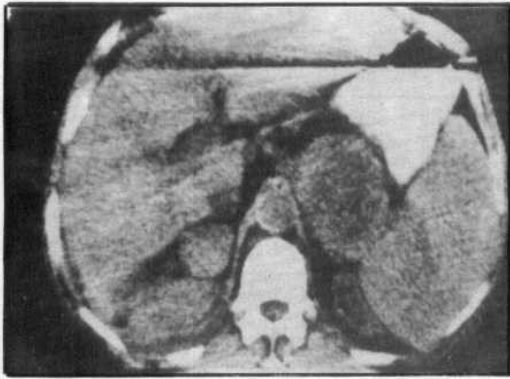


Fig. 4 (A)

Multiple endocrine adenomatosis Type II A CT scan demonstrates bilateral pheochromocytoma and the patient had medullary thyroid carcinoma

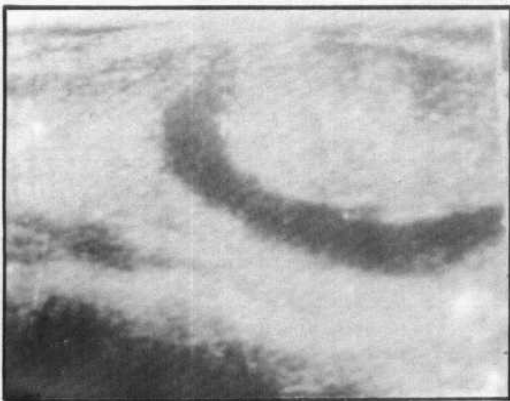


Fig. 4 (B)

The echogram of the thyroid gland of the same patient showed thyroid tumour 4.1 x 2.7 cm of nearly smooth outline. The peripheral structure of tumour showed cystic degeneration. The cytologic diagnosis by aspiration biopsy was partially cystic degeneration of thyroid carcinoma.

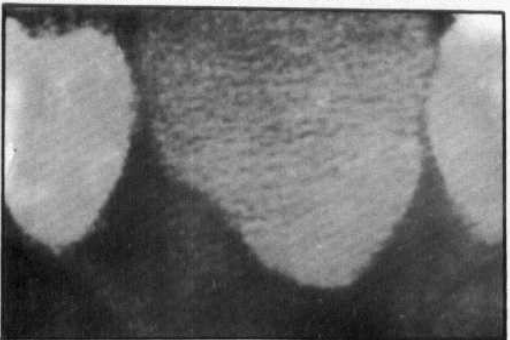


Fig. 5

Pheochromocytoma arising in the posterior portion of the right bladder wall.

Excretory urography is useful only when the adrenal gland becomes enlarged enough to displace the kidneys (Lang, 1966) and even when

excretory urography is combined with nephrotomography, adrenal masses less than 2.5 cm in diameter are usually undetectable (Karstaedt et al 1978). Radiologic techniques such as retroperitoneal pneumography, adrenal angiography and venography are too invasive to be used as screening procedures (Mitty et al 1973).

Adrenal scintigraphy with ¹²⁵I-labeled iodocholesterol or (6B - 1) iodomethyl - 19-norcholes - 5 - (10) - en - 3B - of (NP- 59) is useful for localizing functioning adrenal cortical neoplasms, but the examination takes up to 3 weeks to complete and requires a relatively high radiation exposure (Troncone et al 1977). Gray scale ultrasonography can delineate some normal sized adrenal glands and most adrenal masses larger than 2 cm in diameter (Yeh 1980). CT provides the last step in the diagnostic evaluation of patients with possible adrenal disease, because of its diagnostic accuracy and the fact that it is simple, non-invasive and a reproducible method (Korfobkin, et al, 1979). Normal adrenal tumours larger than 1.0 cm in diameter and some as small as 0.5 cm, can be detected (Eghrari et al., 1980).

All patients were referred for CT evaluation of the adrenal glands had clinically and laboratory findings of pheochromocytoma.

The value of CT in diagnosing adrenal lesions is manifold. It is ideal for detecting and localizing lesions of adrenal gland, even when very minute and determine the extent of the lesion and the infiltration of surrounding structures. It is proved to be an accurate diagnostic tool in the 9 cases subjected to our study.

Laursen and Damgaard (1980) reported that most pheochromocytoma are solitary and have a predilection for the right adrenal, but approximately 10 percent are bilateral and 10 Percent are ectopic. In our study, 7 cases were on the right side, one case was bilateral and one case was ectopic in the urinary bladder.

Most frequently, CT identified a unilateral mass with an attenuation of 16 to 70 HU and a normal contralateral gland. Pheochromocytomas when detected are usually larger than 2 cm in diameter and may be entirely solid lesion, may contain both cystic and solid components, or may be almost entirely cystic.

Thomas et al, (1980) reported that the most common extraadrenal locations of

phaeochromocytoma are in the organ of Zuckerkandl, which lies near the origin of the inferior mesenteric artery, in the upper para-aortic region, along the sympathetic nerve chain in the mediastinum, and in the bladder, anus, vagina and coccygeal area. We found one case of ectopic phaeochromocytoma in the wall of the urinary bladder.

Chok et al, (1980) stated that phaeochromocytoma are commonly associated with medullary thyroid carcinoma and parathyroid disease. This triad, termed the MEA II or Sipple syndrome, has a 40 percent incidence of bilateral phaeochromocytoma which increases to more than 70 percent when familial phaeochromocytoma is associated with medullary carcinoma of the thyroid. The phaeochromocytomas in the MEA syndrome are almost exclusively adrenal in origin but often are unsuspected because the patients are frequently normotensive. The detection of a phaeochromocytoma in patients with MEA syndrome is important because surgery for associated tumours may precipitate hypertensive crises. In our study we found one case of medullary thyroid carcinoma with bilateral phaeochromocytoma.

Conclusion :

Normal adrenal glands can be shown on CT in almost all adults by using adjacent or slightly overlapping sections.

There is at present no readily available radiological method which demonstrates both normal and abnormal adrenals to such advantage as computed tomography.

CT has become the primary imaging technique in suspected phaeochromocytoma whether in the supra renal or ectopic in origin.

In comparison with the standard radiographic techniques CT can detect adrenal tumours larger than 1 cm in diameter and some as small as 0.5 cm can be detected.

References :

- Chok, J; Freier, D.T.; McCornick, T.L.; Nishiyama, R.H.; Forrest, M.E.; Kaugman, A. and Borlaza, G.S. (1980): AJR, 134:23.
- Eghrari, M; McLoughlin, M.J.; Posen, I.I.; St. Louis, E.L.; Wilron, S.R.; Wise, D.J. and Yeung, H.P.H. (1980): J. comput assist tomogr., 4:71.
- Karstaedt, N.; Sage, S.S.; Stanley, R.J.; Melson, G.L. and Levitt, R.G. (1978): Radiology, 129:723.
- Korobkin, M.; Whitel, E.A.; Kressel, H.Y.; Mors, A.A. and Montagne, J.P. (1979): AJR, 132:231.
- Laung, E.K. (1966): Radiology, 87:35.
- Laursen, K.; Damgaard-Pedersen, K. (1980): AJR, 134:277.
- Mitty, H.A.; Nicolls, G.L. and Gabrilove, J.L. (1973): AJR, 119:564.
- Pillari, G.; Mandon, V.; Guiz, V. and Chen, M. (1982): J. comput assist tomogr., 6:169.
- Sutton, D. (1987): A textbook of radiology and imaging, Fourth Edition, Churchill Livingstone, Vol. 1, Part 4, 1047.
- Thomas, J.L.; Bernardion, M.E.; Samaan, V.A. and Hickey, R.C. (1980): AJR, 135:477.
- Tronccone, L.; Galli, G.; Salvo, D.; Barbareno, A. and Bonoma, L. (1977): Br.J.Radiol., 50:430.
- Yeh, H.C. (1980): AJR, 135:167.